

Clinical evaluation of fiber-reinforced epoxy resin posts and cast post and cores

MARCO FERRARI, MD, DDS, PHD, ALESSANDRO VICHI, DDS & FRANKLIN GARCÍA-GODOY, DDS, MS

ABSTRACT: ***Purpose:*** This retrospective study evaluated treatment outcome of cast post and core and Compositopost systems after 4 yrs of clinical service. ***Materials and Methods:*** 200 patients were included in the study. They were divided in two groups of 100 endodontically treated teeth restored with a post. Group 1: Compositopost systems were luted into root canal following the manufacturer's instructions. Group 2: Cast post and cores were cemented into root canal preparations with a traditional technique. The patients were recalled after 6 months, 1, 2 and 4 yrs and clinical and radiographic examinations were completed. Endodontic and prosthodontic results were recorded. ***Results:*** Group 1: 95% of the teeth restored with Compositoposts showed clinical success; 3% of these samples were excluded for noncompliance and 2% showed endodontic failure. Group 2: Clinical success was found with 84% of teeth restored with cast post and core. 2% of these samples were excluded for noncompliance, 9% showed root fracture, 2% dislodgment of crown and 3% endodontic failure. Statistical evaluation showed significant differences between Groups 1 and 2 ($P < 0.001$). The results of this retrospective study indicated that the Compositopost system was superior to the conventional cast post and core system after 4 yrs of clinical service. (*Am J Dent* 2000;13:15B-18B).

CLINICAL SIGNIFICANCE: Compositoposts can be used routinely for restoring endodontically-treated teeth. Fiber posts might eliminate the risk of root fractures.

CORRESPONDENCE: Dr. Marco Ferrari, Piazza Attias 19, Livorno 57120, Italy. Fax: 39 0586 892283; E-mail: md3972@mclink.it

Introduction

Endodontically-treated teeth with defective coronal aspects very often need to be restored with a post and core as foundation for the final restoration.¹⁻³ In the last decades, cast posts were most commonly used because of their favorable physical properties and biocompatibility. Unfortunately, several disadvantages associated with conventional cast post-and-core were found such as loss of retention of the post or of the crown, potential for post and root fractures and risk of corrosion when different metals were used in the system.⁴⁻⁸ Although several factors are involved, some of these failures can be related to the mechanical properties of the posts.⁹ In particular, root fractures were mainly correlated to the shape and length of the post.¹⁰

The cast post-core systems include components of different rigidity. Since the more rigid component (post), is able to resist forces without distortion, stress is transferred to the less rigid one (dentin), and causes the failure of it. The difference between modulus of elasticity of dentin and post material is a source of stress for the root structures. Therefore the use of resin-based composite (RBC), glass-ionomers and amalgapins has been advocated with crown coverage¹¹ in order to avoid the insertion of metal posts into the root canal.¹²

A carbon fiber post developed in France and introduced in the U.S. (Compositopost or C-Post^a), was proposed in order to overcome the disadvantages of metal posts.¹³ Carbon fiber posts consist of pyrrolitic carbon fibers arranged longitudinally in an epoxy resin matrix with the carbon component constituting 64% of the structure. The carbon fiber post exhibits high fatigue and tensile strength, and has a modulus of elasticity (stiffness) comparable to dentin.^{13,14} Its chemical nature is compatible with the Bis-GMA resins commonly used in bonding procedures. This post can be bonded within

root canal space with polymer dentin bonding agents and resin cements of similar flexibility, and effectively transmit stresses between the post and the root structure, reducing stress concentration and preventing fracture.^{13,14}

The Compositopost system is relatively new, so there are only few long-term studies of clinical performances.¹⁵⁻¹⁷ These studies showed that the 2-3 yr clinical performance of carbon fiber posts was excellent.¹⁵⁻¹⁷

This retrospective study evaluated the 4-yr clinical performance of endodontically-treated teeth restored either with carbon fiber posts or cast posts.

Materials and Methods

Between January and July 1995, 200 endodontically-treated teeth with severe loss of tooth structure were selected and randomly divided into two experimental groups of 100 samples each. All roots were endodontically-treated with the lateral condensation of gutta-percha and eugenol-free sealer. After no less than 48 hrs from the endodontic treatment, the roots were prepared for receiving a post. In the molar roots only one post was placed, in the palatal root of maxillary and in distal root of mandibular teeth.

Group 1: After selection of appropriate drill size, the root canal spaces were prepared using preshaping and finishing drills^a for a length of 9 mm. At least 4 mm of gutta-percha was left apically to seal the root apex. Then, the posts were tried in and consequently shortened with a diamond bur. Compositopost were bonded with All-Bond 2^b and C & B^b resin cement strictly following the manufacturers' instructions. The teeth were built-up with Bis-Core^b self-curing RBC.

Group 2: The roots of this group were prepared to receive a cast post-and-core. Then an impression of root canal spaces was made with a reversible hydrocolloid material (Optiloid^c)

Table 1. Clinical distribution of cast and fiber posts.

		Incisors	Canines	Premolars	Molars	Total
Group 1	Maxilla	12	13	19	13	57
	Mandible	9	10	12	12	43
Group 2	Maxilla	15	18	18	9	60
	Mandible	6	10	19	14	40

Table 2. Results at 4-yr recall of cast and fiber posts.

Group 1 - Carbon fiber posts		
Teeth excluded for noncompliance		3%
Failures (periapical lesions 2%)		2%
Successful		95%
Group 2 - Cast post-and-cores		
Teeth excluded for noncompliance		2%
Failures		14%
Dislodgment of the crowns		2%
Root fractures		9%
Periapical lesions		3%
Successful		84%

and poured in Type IV stone (Fuji Rock^d). The post-and-cores were waxed and cast in precious alloy (Medior 3^c) finished and tried into the root canals. The clinical procedures of post cementation were accomplished using zinc phosphate cement (Zinc Cement^f).

The abutments were temporized with resin crowns cemented with eugenol-free cement. All teeth received a porcelain-fused-to-metal crown as the final restoration.

Periapical radiographs and clinical examination were performed before post cementation, immediately after, 6 months, 1, 2 and 4 yrs after crown cementation in order to evaluate crown retention, secondary caries and periapical and periodontal tissues. The radiographs were taken with the long-cone technique and ultraspeed film.^g The radiographs were examined with approximately x5 magnification. Comparisons were made with radiographs taken before, immediately after treatment and at recalls. Of the opposing occluding teeth, 60% had fixed restorations, 5% were restored with removable partial denture, 15% occluded with unrestored teeth, 20% were in occlusion with vital teeth restored with amalgam or RBC.

The rate of success was assessed by clinical and intraoral radiographic examinations. The outcome was considered successful if the post and cores were *in situ*, without secondary caries, clinical or radiographic signs of technical failures, endodontic infection, loss of retention, root fracture or post fracture. A single operator carried out the clinical evaluation in restored teeth. The frequency of types of teeth treated is shown in Table 1. All patients had previously been included in an individual recall program. The patients were recalled after 6 months, 1, 2 and 4 yrs. The length of clinical service of Group 1 and 2 samples at last recall was 4 yrs.

Actuarial Life Table statistical analysis and Mautel-Hauszel comparison of survival curve was performed at a 95% level of confidence.

Results

The results are summarized in Table 2. Representative cases are illustrated in Figures 1-4.

Group 1: Of the 100 teeth treated in Group 1, three (3%) were excluded for missing the last recall exam. Due to periapical

lesions, two teeth needed to be retreated endodontically. The remaining 95 teeth were classified as successful. No dislodgment or fracture of posts or roots was observed in the recalled 97 teeth. Dental caries were not detected in the post-treated teeth. Thus, no technical failures attributable to the carbon fiber post-and core system were recorded.

Group 2: Of the 100 teeth treated with cast post-and-cores, two (2%) were excluded for missing the the 4-yr recall exam. Due to periapical lesions, three teeth needed to be retreated endodontically. Nine teeth showed root fracture and two dislodgment of the crown. All these situations were noted at the last recall. No caries, fracture or dislodgment of the posts were noted.

Radiographic examination at the 4-yr recall showed evidence of root fracture of nine roots. Four root fractures were noted in the abutments of two bridges of two different patients. The other five root fractures were found on teeth covered by single-unit porcelain fused-to-metal crowns.

The results of statistical analysis showed a significant difference between Groups 1 and 2 ($P < 0.001$).

Discussion

There are conflicting reports on the ability of metal posts to reinforce endodontically-treated teeth.¹⁸⁻²⁰ A more recent review of the literature suggests that many endodontically-treated teeth are not reinforced with the use of a metallic post, but the role of the post is only to support the abutment build-up material and consequently the final restoration.^{10,21,22}

There are only few clinical studies of metallic-post success and failures. Sorensen & Martinoff²⁰ noted 8.6% failures as a result of post dislodgement, root fractures or post perforations. Weine *et al*²³ reported 6.5% failures after 10 yrs or more and Torbjorner *et al*⁸ reported 8.3% failures after 2-3 yrs. Mentink *et al*²⁴ showed a success rate of 82% for anterior teeth and that recementation was the most frequent type of failure.

The data of this clinical study related to cast posts showed 14% of failures were found for cast posts after 4 yrs of clinical service. Root fracture was the most frequent type of failure. One of the reasons for root fracture is that with the cast post and core the stress can be concentrated in uncontrolled areas where a fracture can start. Another reason can be that the cast post has retention due to friction along root walls which can transmit the stress directly to root structure: in the area where dentin walls are thinner and consequently less resistant, a fracture can take place.

Endodontic failure (periapical lesions) was observed in 2% and 3% of Groups 1 and 2, respectively. The retreatment of teeth built up with fiber posts is simple, because the fiber post structure can be easily removed with a high speed bur and a drill. The retreatment of teeth restored with cast posts was more difficult because the metallic posts must be removed with a diamond bur mounted in a handpiece. The latest procedure required more working time, was more risky for root integrity and was more difficult to be completed than that followed for retreating the two teeth of Group 1. Another advantage is that the fiber post technique is less time-consuming than the technique for preparing a cast post and core in the laboratory.

An ideal post should have a modulus of elasticity close to that of root dentin and carbon fiber posts fulfilled this require-

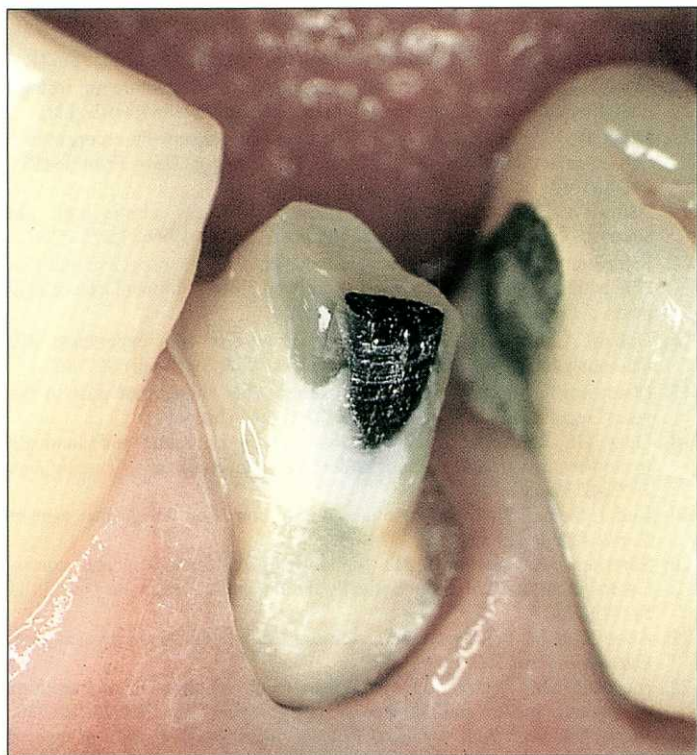


Fig. 1. Carbon fiber post cemented in a premolar.

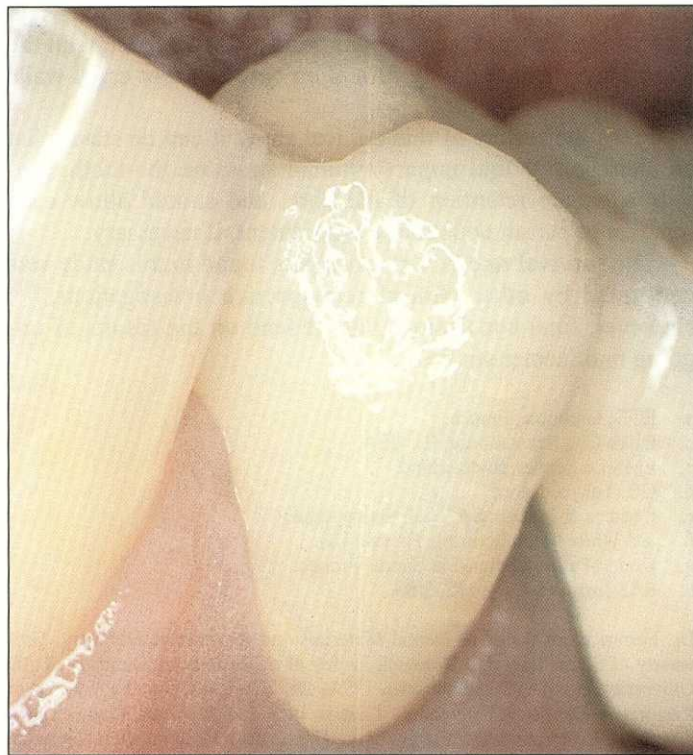


Fig. 2. 4-yr result of a porcelain-fused-to-metal crown of case shown in Fig. 1.

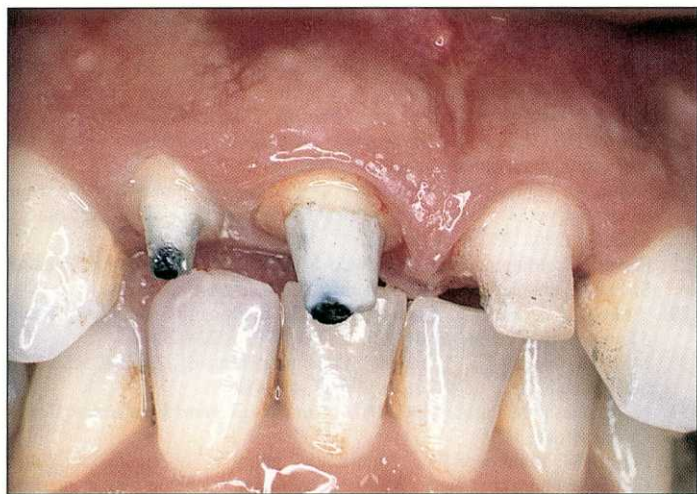


Fig. 3. Carbon fiber post cemented in central and lateral incisors.

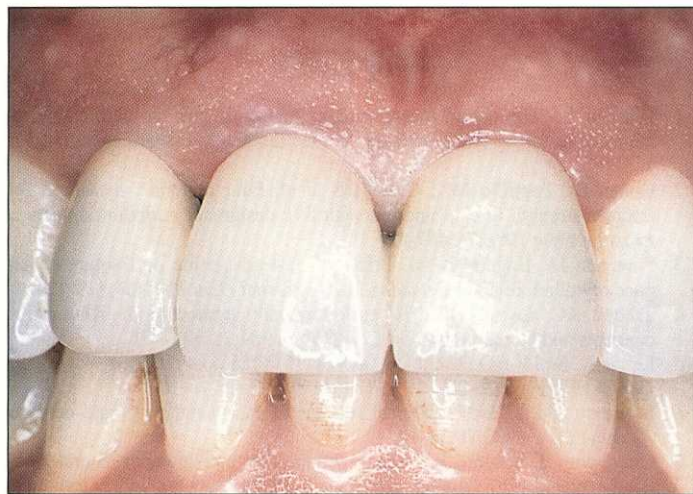

Fig. 4. 4-yr result of porcelain-fused-to-metal crowns of case shown in Fig. 3.

ment.¹³ When a load was applied with an angle of approximately 35° to the long axis of the post, the modulus of elasticity of carbon fiber posts was approximately 21 GPa, while that of the dentin is approximately 18 GPa. More recently, similar results were obtained¹⁴ when a load was applied with an angle of 45° to the long axis of the post.

Recently, a cycling load test evaluating post-core restorations of teeth covered with metal crowns showed that carbon fiber post-composite core restorations were less likely to produce root fractures than stainless steel post-composite cores.²⁵ Other *in vitro* studies confirmed that the fracture type is more benign when fiber post is used than when metal posts are used: with the metallic posts a relatively high proportion of the tooth fractures involved the root structures.²⁵⁻²⁷

Compositopost dowels are passive and are designed to be used with a bonding technique. A bonding system and resin

cement establish a strong bond to the root canal dentin walls after removal of the smear-layer, demineralized dentin and increased surface available for bonding.²⁸ The major elements which contribute to bond strength are tubular resin tag formation when tags bond well to the tubule walls,²⁹ resin infiltration into demineralized tubular dentin and side branches of the tubules.^{30,31} Several three-step and "one-bottle" systems were tested in endodontically-treated teeth and resin tag, adhesive lateral branch and hybrid layer formation was demonstrated under clinical conditions.³² However, for optimal results the manufacturer's instructions must be followed carefully.

The influence of different cements on retention of posts has been the subject of recent research.³³⁻³⁶ Several clinical advantages of the bonding/luting procedures of fiber posts are detectable. A study demonstrated that posts cemented with enamel-dentin bonding resin cements exhibited less leakage

than when cemented with other cements (glass-ionomer and zinc phosphate) and these results were also correlated with the hybrid layer and resin tag formation between root canal walls and resin.^{37,38}

From the results of this clinical study it can be stated that an ideal post should impart minimal stress on the tooth, provide adequate retention of the core, and should allow easy removal to permit endodontic retreatment, if necessary.

The survival rate of Composiposts found in this study was confirmed by other clinical retrospective investigations.¹⁵⁻¹⁷ However, final conclusions will depend on the results of ongoing multicenter studies.

- a. RTD, Grenoble, France.
- b. Bisco Co., Schaumburg, IL, USA.
- c. EMS, Le Sentier, Switzerland.
- d. GC, Tokyo, Japan.
- e. Cendres & Metaux SA, Biel, Switzerland.
- f. SS White Manufacturing, Bristol, UK.
- g. Kodak-Pathe, Chalon-Sur Saone, France.
- h. SAS Institute, Cary, NC, USA.

Dr. Ferrari is Professor of Dental Materials and Restorative Dentistry, University of Siena, Italy and Research Professor of Restorative Dentistry, Tufts University, Boston, Massachusetts, USA. Dr. Vichi is Clinical Professor of Restorative Dentistry, University of Siena, Italy and Assistant Research Professor of Restorative Dentistry, Tufts University, Boston, Massachusetts, USA; Dr. Garcia-Godoy is Professor and Director, Clinical Materials Research, Department of Restorative Dentistry, University of Texas Health Science Center, San Antonio, Texas, USA.

References

1. Gutman JL. The dentin-root complex: Anatomic and biologic considerations in restoring endodontically treated teeth. *J Prosthet Dent* 1992;67:458-467.
2. Cohen BI, Pagnillo MK, Condos S et al. Four materials measured for fracture strength in combination with five designs of endodontic posts. *J Prosthet Dent* 1996;76:487-495.
3. Sorensen JA, Engelman MJ. Effect of post adaptation on fracture resistance of endodontically treated teeth. *J Prosthet Dent* 1990;64:419-424.
4. Trabert KC, Cooney JP. The endodontically treated tooth. Restorative concepts and techniques. *Dent Clin N Am* 1984;28:923-951.
5. Lewis R, Smith BG. A clinical survey of failed post retained crowns. *Br Dent J* 1988; 165:95-97.
6. Morgano SM, Milot P. Clinical success of cast metal posts and cores. *J Prosthet Dent* 1993;70:11-16.
7. Goodacre CJ, Spolnik KJ. The prosthodontic management of endodontically treated teeth: A literature review. Part I. Success and failure data, treatment concepts. *J Prosthodont* 1994;3:243-250.
8. Torbjoner A, Karlsson S, Odman PA. Survival rate and failure characteristics for two post designs. *J Prosthet Dent* 1995;73:439-444.
9. Hatziriakos AH, Reisis GI, Tsingos N. A 3 year postoperative evaluation of posts and cores beneath existing crowns. *J Prosthet Dent* 1992;67:454-458.
10. Stockton LW. Factors affecting retention of post systems: A literature review. *J Prosthet Dent* 1999;81:380-385.
11. Lin LM, Langeland K. Vertical root fracture. *J Endod* 1982;8:558-621.
12. Trope M, Maltz DO, Tronstadt L. Resistance to fracture of restored endodontically treated teeth. *Endod Dent Traumatol* 1985;1:108-111.
13. Duret B, Reynaud M, Duret F. Un nouveau concept de reconstitution corono-radulaire: Le composiposte (1) *Chirurg Dent France* 1990; 540:131-141.
14. Asmussen E, Peutzfeldt A, Heitmann T. Stiffness, elastic limit, and strength of newer types of endodontic posts. *J Dent* 1999;27:275-278.
15. Fredriksson M, Astback J, Pamenius M, et al. A retrospective study on 236 patients with teeth restored by carbon fiber-reinforced epoxy resin posts. *J Prosthet Dent* 1998; 80:151-157.
16. Dallari A, Rovatti L. Six years of *in vitro/in vivo* experience with Composipost. *Compend Contin Educ Dent* 1998;20 (Suppl):S57-S63.
17. Mannocci F, Vichi A, Ferrari M. Carbon fiber versus cast post: A two years' recall study. *J Dent Res* 1998;77:1259 (Abstr 419).
18. Guzy GE, Nicholls JI. *In vitro* comparison on intact endodontically treated teeth with and without endo-post reinforcement. *J Prosthet Dent* 1979;42:39-44.
19. Rud J, Omnell KA. Root fractures due to corrosion. Diagnostic aspects. *Scand J Dent Res* 1970;78:397-403.
20. Sorensen JA, Martinoff JT. Intracoronal reinforcement and coronal coverage: A study of endodontically treated teeth. *J Prosthet Dent* 1984; 51:780-784.
21. Abou-Rass M. Post and core restoration of endodontically treated teeth. *Curr Opin Dent* 1992;2:99-107.
22. Morgano SM. Restoration of pulpless teeth: Application of traditional principles in present and future contexts. *J Prosthet Dent* 1996;75:375-380.
23. Weine FS, Wax AH, Wenckus P, et al. Retrospective study of tapered, smooth post systems in place for 10 years or more. *J Endod* 1991;17:293-297.
24. Mentik AG, Meenwiser R, Kayser AF, et al. Survival rate and failure characteristics of the all metal post and core restoration. *J Oral Rehabil* 1993;20:455-461.
25. Martínez-Insua A, Da Silva L, Rilo B, et al. Comparison of the fracture resistances of pulpless teeth restored with a cast post and core or carbon-fiber post with a composite core. *J Prosthet Dent* 1998; 80: 527-532.
26. Purton DG, Payne JA. Comparison of carbon fiber and stainless steel root canal posts. *Quintessence Int* 1996; 27: 93-97.
27. Vigié G, Malquarti G, Vincent B, et al. Epoxy/carbon composite resins in dentistry: Mechanical properties related to fiber reinforcements. *J Prosthet Dent* 1994;72:245-249.
28. Ferrari M, Mannocci F, Cagidiaco MC, et al. Bonding to root canal: Structural characteristics of the substrate. *Am J Dent*, In press.
29. Titley K, Chermeky R, Chen A, et al. The composition and ultrastructure of resin tags in etched dentin. *Am J Dent* 1995;8:224-230.
30. Mjör IA, Nordahl I. The density and branching of dentinal tubules in human teeth. *Archs Oral Biol* 1996;41:401-412.
31. Nakabayashi N, Pashley DH. *Hybridization of dental hard tissue*. Berlin: Quintessence, 1998.
32. Ferrari M, Mannocci F. A "one-bottle" adhesive system for bonding a fibre post into a root canal: An SEM evaluation of the post-resin interface. *Int Endod J*, in press.
33. Standlee JP, Caputo AA, Hansson EC. Retention of endodontic dowels: Effects of cement, dowel length, diameter and design. *J Prosthet Dent* 1978;40:645-649.
34. Kurer HG, Come EC, Grant AA. Factors influencing the retention of dowels. *J Prosthet Dent* 1977;38:515-525.