

Rehabilitation of Endodontically Treated Teeth Using the Radiopaque Fiber Post

CE 2

Philip L. Brown, DDS
Manager
International Professional Relations
and Research
Bisco, Inc
Schaumburg, Illinois

Norman L Hicks
Consultant
RTD
St. Egreve, France

Abstract: *Metallic posts fall short of satisfying contemporary guidelines for ideal post/core rehabilitation. Along with technological improvements in adhesive resins, cements, and composite restoratives, the evolution of fiber-reinforced posts allows the rehabilitation of endodontically treated teeth with greater esthetics and virtually no predisposition to root fracture. At least one fiber post system now complies with all of the ideal post characteristics described in the endodontic text. This article describes the potential for displacement of metal posts by low-modulus fiber posts, the differences between them, and the development and placement of a radiopaque, translucent, double-tapered fiber post.*

Post/core rehabilitation is an integral part of contemporary dental therapy, and like other aspects of restorative dentistry, has benefited from new materials and technologies adapted from other industries and medical disciplines. For nearly a century, the standard technique for restoration of badly broken down endodontically treated teeth consisted almost exclusively of either a cast metal post/core or a prefabricated metal post with an amalgam core buildup. Despite the eminent risk of galvanic response, corrosion, microleakage and, worst of all, root fracture,¹⁻⁶ the use of metallic posts remained the standard of care (and dental education) into the 1990s, presumably for lack of viable alternatives. The last decade of the twentieth century witnessed the advent and adoption of reliable fourth and fifth generation adhesive bonding agents, as well as vast improvements in composite restoratives. Both of these advancements have improved clinicians' capabilities and confidence.

The eighth edition of *Pathways of the Pulp*⁷ proposes that the ideal dowel (post) should offer as many as possible of the following clinical features:

- Maximum protection of the root.
- Maximum retention of the core and crown.
- Maximum protection of the crown margin seal.
- Pleasing esthetics, when indicated.
- High radiographic visibility.
- Retrievability.
- Biocompatibility.

The Problem

There are some dichotomies inherent in the use of metallic posts. For example, parallel metal posts exhibit greater in vitro retention (using traditional cements) than tapered ones, but require more profound dentin removal apically (Figure 1). Tapered metal posts (including cast posts) can more closely approximate the taper of the prepared canal, while at the same time act as a wedge. This concentrates stresses inside the tooth and predis-

Learning Objectives:

After reading this article, the reader should be able to:

- identify the characteristics of the "ideal" endodontic post.
- discuss the pros and cons of fiber vs metal posts.
- describe the advancements inherent in a double-taper post shape.

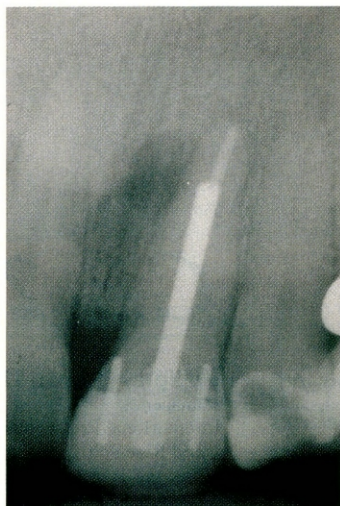

Figure 1—
Traditional prefabricated metal posts.

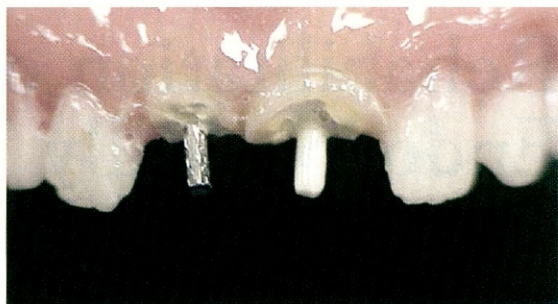


Figure 2—Esthetics of metal vs white fiber post.

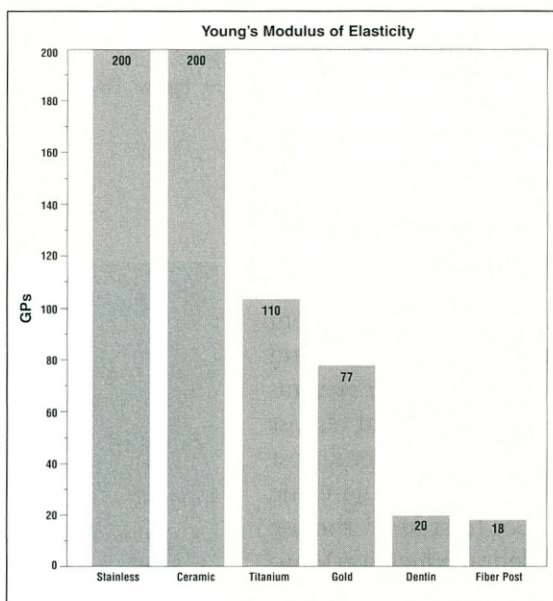


Figure 3—Elastic modulus of post materials.

poses it to root fracture.⁸ Stainless steel is considered adequately strong (tensile) for the indication, but is also quite capable of corroding.² Neither stainless steel, titanium, or casting alloys are esthetic (Figure 2), so their use should be limited to posterior/porcelain-fused-to-metal (PFM) treatment plans. Their high Young's modulus of elasticity (100 GPa to 200 GPa) is 5 to 10 times that of the dentin, which contributes to the transference of functional and traumatic stresses to the already-compromised tooth.⁸

The Remedy

In the late 1980s, two practicing dentists in Grenoble, France, borrowing technology used in the automotive and aerospace industries, developed, patented, and commercialized an endodontic post constructed of fiber-rein-

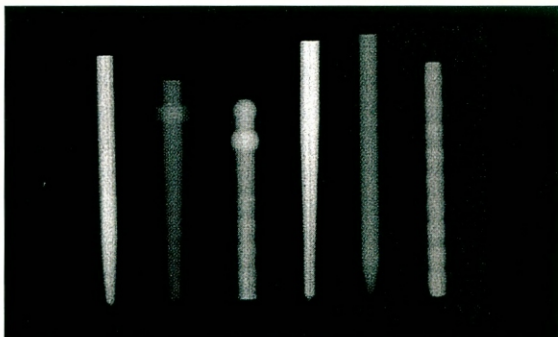


Figure 4—Comparative radiopacity of fiber posts.

forced composite. While the original version was not radiopaque or esthetic, it did fulfill five of the seven "ideal dowel characteristics" mentioned previously, including atraumatic removal in several minutes^{9,10} and biocompatibility.¹¹ The protection (mechanical harmony) aspect was accomplished via the fiber-reinforced composite post, which possesses high strength and a modulus of elasticity similar to that of dentin: 18 GPa to 50 GPa (Figure 3). This, in turn, distributes stress in a completely different pattern from any metal, and more like natural tooth structure.¹²

Continued Improvement

Encouraged by favorable results in comparative in vitro testing¹³⁻¹⁵ and clinical success (no root fractures, negligible decementations),¹⁶⁻²⁰ RTD/Bisco have provided a sequence of advanced models, including the radiopaque carbon fiber, followed by nonradiopaque esthetic posts. Other well-known companies have introduced their own brand of esthetic, but nonradiopaque fiber posts (Figure 4). The best known of these (ParaPost[®] White^a and FibreKor^{®b}) are parallel posts which, like their metal counterparts, are often too narrow at the coronal end and too thick at

^aColtène/Whaledent, Inc, Mahwah, NJ 07430; (800) 221-3046

^bPentron Clinical Technologies, Wallingford, CT 06492; (877) 677-8844

Figure 5—Measurements of canal width and taper in endodontically treated teeth.

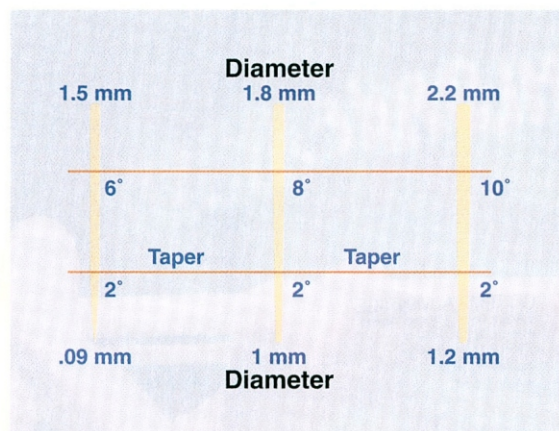
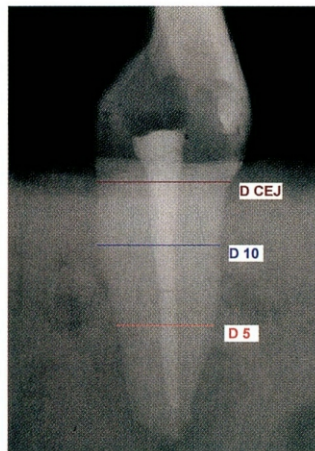

Figure 7—Three post diameters; each with two tapers.

the apical end, thus requiring additional dentin removal.

Esthetic posts also vary in strength, fatigue resistance, and resistance to fracture in endodontically treated teeth from brand to brand. For example, Cormier and colleagues¹⁰ determined that the esthetic RTD/Bisco post systems were superior to the FibreKor[®] post, while Akkayan and Gulmez²¹ proved the D.T. LIGHT-POST^{®c} resisted fracture better than the ParaPost[®] White or the zirconia Cosmopost^d. This may correlate to the inherent differences in their makeup; the type of fibers (quartz, glass, zirconia), the volume of fibers used (37% to 64%), the matrix material (epoxy, Bis-GMA), and the manufacturing processes.

The Latest Generation

Lambjerg-Hansen and Asmussen²² observed that dowels with a parallel coronal portion and a conical apical portion provide stability and address the tapered nature of the

^cRTD, France, distributed by BISCO Dental Products, Schaumburg, IL 60193; (800) BIS-DENT

^dIvoclar Vivadent, Amherst, NY 14228; (800) 533-6825

Figure 6—Prototype posts evaluated for fit and adaptation.



Figure 8—Radiograph of prepared canal.

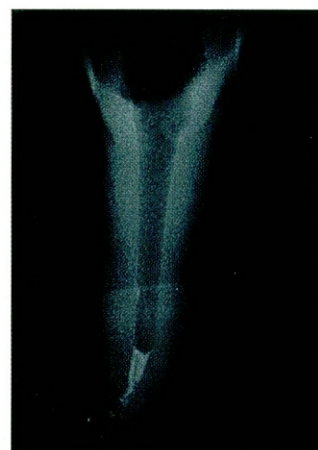
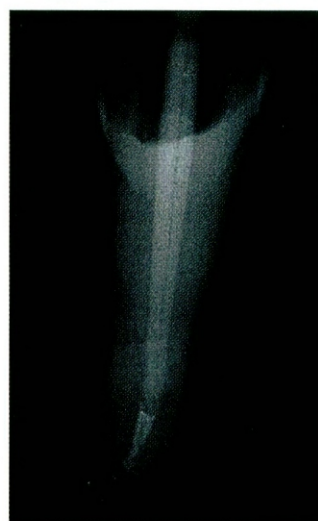
Figure 9—Radiopaque D.T. LIGHT-POST[®] in canal.



canal. It was this paradigm that led Boudrias and Colleagues²³ at the University of Montreal to investigate and develop parameters and specifications for a low-modulus post system that conforms to the typical root canal preparation, rather than adapting the canal to accommodate the typical post. To achieve this, they evaluated 967 extracted teeth that had been endodontically treated in clinical

Figure 10—Remove gutta percha and gain access to the canal.

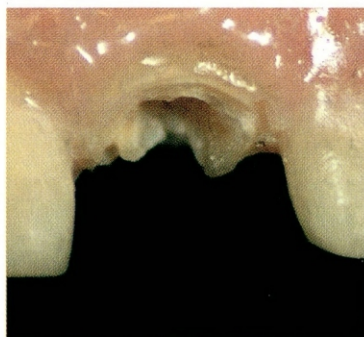


Figure 12—Try-in the post. Remove and clean post and canal with alcohol.

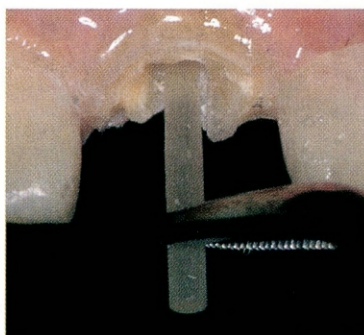


Figure 14—Apply Bisco ONE-STEP[®] to the clean post. (ONE-STEP[®] is recommended because of its high bond strength, low film thickness and light-curing sensitivity.)

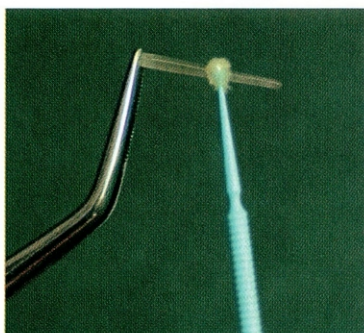


Figure 11—Begin with the universal starter drill, followed by the drill for the selected post size.

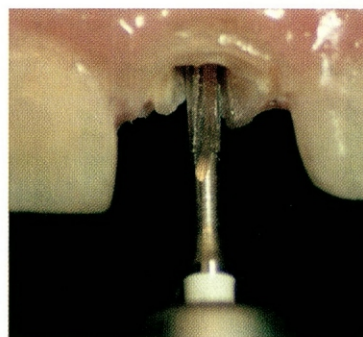


Figure 13—Trim excess length with a bur, diamond or disk. Never use pliers or snippers.

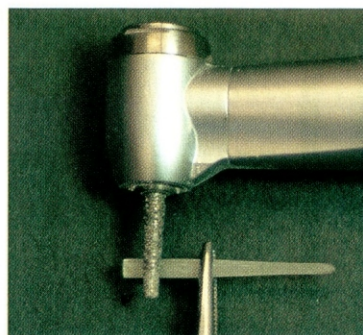



Figure 15—Light-cure the ONE-STEP[®] for 10 seconds from two sides of the post.



training and continuing education courses at the university. Using digital radiography, they documented canal shape, width, diameter, and taper at 5 mm and 10 mm from the apex and at the cemento-enamel junction (CEJ) (Figure 5). Dozens of prototype posts were made and inserted into 346 extracted teeth, which were then sectioned sagittally and longitudinally to examine fit and adaptation (Figure 6).

From this database, Sakkal and Boudrias were able to refine specifications for three sizes of posts that would conserve dentin at the apical end, provide high-performance “bulk” at the coronal end, and maintain intimate adaptation along the entire post length. Evaluation at the University of Montreal^{24,25} and other dental schools²⁶ confirm this. The resulting product is available commercially as the double taper (D.T.) LIGHT-POST[®]. These posts necessarily have one taper in the apical 5 mm

(2°), another taper (6° to 10°) in the next 5 mm, and a parallel (180°) coronal end (Figure 7). The post has been engineered to demonstrate the same desirable mechanical properties as its carbon-fiber predecessor, but also meets the last two remaining requirements of the “ideal dowel” criteria: radiographic visibility (Figures 8 and 9) and esthetics. The post is highly translucent (neutral color) and can be used as a fiber-optic light guide, to aid in the polymerization of adhesives and dual-cured cements deep inside the tooth.^{27,28}

Clinical Placement Technique

The placement technique for the D.T. LIGHT-POST[®] is illustrated in Figures 10 through 25 on an extracted tooth for visual clarity. In clinical application, the usual isolation techniques are highly recommended. Use a radiograph to determine the appropriate size post.

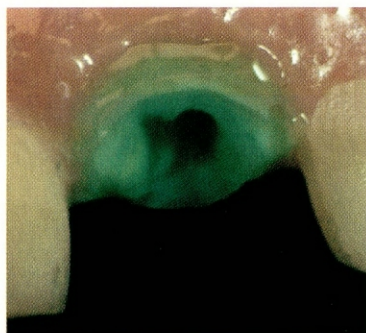


Figure 16—Etch the canal and involved tooth structure for 15 seconds with UNI-ETCH[®] with BAC.

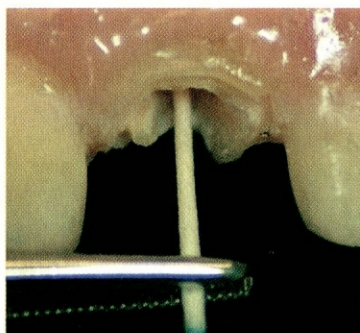


Figure 17—Rinse and remove excess water with a paper point. Do not desiccate.

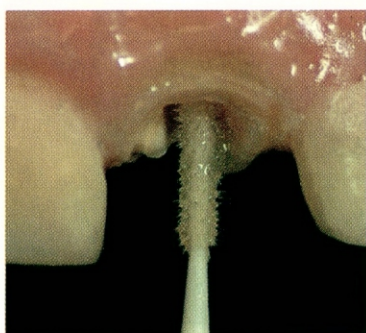


Figure 18—Apply two coats of ONE-STEP[®] to the canal and involved coronal tooth structure.

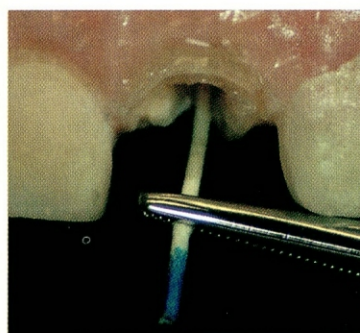


Figure 19—Remove excess ONE-STEP[®] with a paper point. AIR-DRY to evaporate solvent.

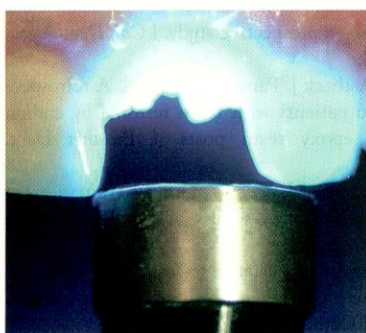


Figure 20—Light-cure ONE-STEP[®] for 10 to 20 seconds.

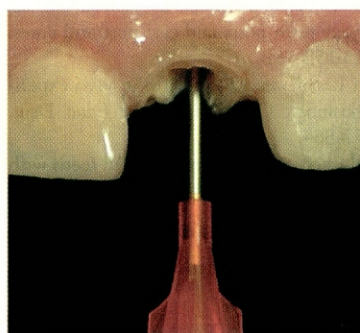


Figure 21—Mix and syringe DUO-LINK[™] dual-cure cement into the canal.

Disclosure

The authors of this article received grant/research support from Bisco, Inc, and RTD.

References

- Christensen GJ. Posts and cores: state of the art. *J Am Dent Assoc*. 1998;129:96-97.
- Angmar-Mansson B, Omnell KA, Rud J. Root fractures due to corrosion. 1. Metallurgical aspects. *Odontol Revy*. 1969;20:245-265.
- Gher ME, Dunlap RM. Clinical survey of fractured teeth. *J Am Dent Assoc*. 1987;114:174-179.
- Goodacre CJ, Spolnik KJ. The prosthodontic management of endodontically treated teeth: a literature review. Part I. Success and failure data, treatment concepts. *J Prosthodont*. 1994;3:243-250.
- Weine FS. *Endodontic Therapy*. 5th ed. St Louis, Mo: Mosby Yearbook;1976:756-781.
- Hatzikyriakos AH, Reisis GE, Tsingos N. A 3-year postoperative clinical evaluation of posts and cores beneath existing crowns. *J Prosthet Dent*. 1992;67:454-458.
- Cohen S, Burns CF. *Pathways of the Pulp*. 8th ed. St. Louis, Mo: Mosby Yearbook;2002:773-775.
- Rengo S. Behavior of RTD fiber posts in Finite Element Analysis (FEM) on three-dimensional models. *Proceedings from the 3rd International Symposium*, S. Margherita Ligure, Italy. 1999;20-27.
- Sakkal S. Carbon-fiber post removal technique. *Compend Contin Educ Dent*. 1996;17(suppl): S86.
- Cormier CJ, Burns DR, Moon P. In vitro comparison of the fracture resistance and failure mode of fiber, ceramic, and conventional post systems at various stages of restoration. *J Prosthodont*. 2001;10:26-36.
- Torbjorner A, Karlsson S, Syverud M, et al. Carbon fiber reinforced root canal posts: mechanical and cytotoxic properties. *Eur J Oral Sci*. 1996;104:605-611.
- Duret B, Duret F, Reynaud M. Long-life physical property preservation and postendodontic rehabilitation with the Composipost. *Compend Contin Educ Dent*. 1996; 17(suppl): S50-S56.
- Isidor F, Odman P, Brondum K. Intermittent loading of teeth restored using prefabricated carbon fiber posts. *Int J Prosthodont*. 1996;9:131-136.
- Martinez-Insua A, da Silva L, Rilo B, et al. Comparison of the fracture resistances of pulpless teeth restored with a cast post and core or carbon fiber post with a composite core. *J Prosthet Dent*. 1998;80:527-532.
- Dean JP, Jeanson BG, Sarkar N. In vitro evaluation of a carbon fiber post. *J Endod*. 1998; 24:807-810.
- Ferrari M, Vichi A, Garcia-Godoy F. Clinical evaluation of

Figure 22—Seat the post with gentle passive pressure.

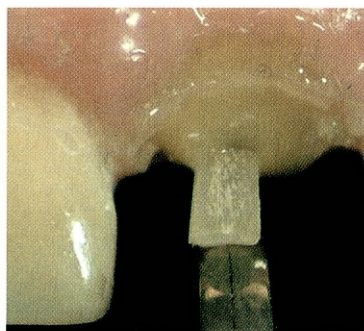


Figure 24—Place, light-cure, and trim LIGHT-CORE build-up composite.




Figure 23—Stabilize the post and cement by light curing from the occlusal aspect and through the post.

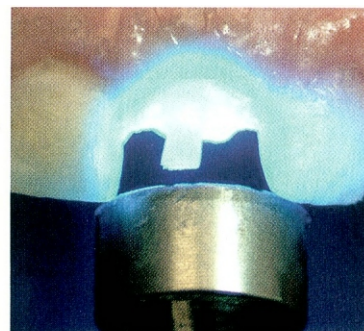
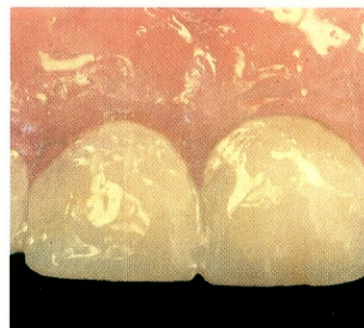


Figure 25—Proceed with steps for definitive prosthesis.



fiber-reinforced epoxy resin posts and cast post and cores. *Am J Dent.* 2000;13:15B-18B.

17. Dallari A, Rovatti L. Six years of in vitro/in vivo experience with Composipost. *Compend Contin Educ Dent.* 1996;17(suppl):S57-S64.
18. Glazer B. Restoration of endodontically treated teeth with

carbon fibre posts—a prospective study. *J Can Dent Assoc.* 2000;66:613-618.

19. Fredriksson M, Astback J, Pamenius M, et al. A retrospective study of 236 patients with teeth restored by carbon fiber-reinforced epoxy resin posts. *J Prosthet Dent.* 1998;80:151-157.
20. Scotti R, Malferrari S, Monaco C. Clinical evaluations of quartz fiber posts: 30 months results [abstract]. *J Dent Res.* 2002;81:Abstract 2657.
21. Akkayan B, Gulmez T. Resistance to fracture of endodontically treated teeth restored with different post systems. *J Prosthet Dent.* 2002;87:431-437.
22. Lambjerg-Hansen H, Asmussen E. Mechanical properties of endodontic posts. *J Oral Rehabil.* 1997;24:882-887.
23. Boudrias P, Sakkal S, Petrova Y. Anatomical post design meets quartz fiber technology: rationale and case report. *Compend Contin Educ Dent.* 2001;22:337-348.
24. Sakkal S, Boudrias P. New developments in fiber post systems: the DT-Post one step closer to the ideal shape. *Proceedings from the 4th International Symposium, S. Margherita Ligure, Italy.* 2000;10-14.
25. Boudrias P, Sakkal S, Yulian S. Anatomical post design applied to quartz fiber/epoxy technology: a conservative approach. *Oral Health.* 2001;9:16.
26. Scotti R, Malferrari S. Prosthetic aspects of endodontically treated tooth restoration; *Proceedings from the 5th International Symposium, S. Margherita Ligure, Italy.* 2001;27-33.
27. Bassi MA. Light diffusion through double taper quartz-epoxy fiber posts. *Proceedings from the 5th International Symposium, S. Margherita Ligure, Italy.* 2001; 21-26.
28. Sawada N, Hikage S, Sakaguchi K. Shape of composite resins photopolymerized by the translucent post. *J Dent Res.* 2002;81:Abstract 2569.

Finally,
A Pressure Indicating Paste
That's Easy To Use

...And Even Easier To Clean.

Specially formulated to be more user friendly than other brands currently in use, Detail brushes on smoothly and wipes off easily with regular facial tissue. Detail allows you to pinpoint the slightest areas of pressure that may cause either discomfort or displacement.

To obtain additional information on Detail, or a copy of our latest full line Dental Catalog, call

Pflingst & Company, Inc.
105 Snyder Road, South Plainfield, New Jersey 07080
Phone: 908-561-6400, or Fax: 908-561-3213
Exclusive U.S. Distributor