

# Long-term Success of Nonvital, Immature Permanent Incisors Treated With a Mineral Trioxide Aggregate Plug and Adhesive Restorations: A Case Series from a Private Endodontic Practice

Marga H. Ree, DDS, MSc, and Richard S. Schwartz, DDS

## Abstract

This case series evaluated the long-term clinical outcome of nonvital immature teeth treated with mineral trioxide aggregate (MTA) as an apical barrier and an adhesive restoration with or without a fiber post. Eighty-three teeth in 72 patients were treated by the first author with an apical MTA plug and an adhesive restoration of composite resin and in 45 of the 83 teeth 1 or more fiber posts. All of the patients had been referred to the first author's private endodontic practice with at least 1 immature tooth with signs of pulpal necrosis and subsequent apical periodontitis that had been caused by a variety of traumatic dental injuries. Three teeth presented had dens invaginatus. Of 83 teeth, 69 teeth in 60 patients were available for follow-up after 5 to 15 years (recall rate = 83%). The mean follow-up time was 8.29 years. No teeth were lost because of a root fracture. Ninety-six percent (66/69) of the recalled teeth were characterized as healed. Based on periapical radiographs and clinical examination, 96% of teeth treated with the MTA barrier technique and adhesive restorations were characterized as "healed" and were in function after 5 to 15 years (mean = 8.29 years). These results indicate that this is a viable and predictable treatment approach for the long-term success of nonvital immature teeth. (*J Endod* 2017; ■:1–8)

## Key Words

Apical barrier technique, clinical outcome, fiber posts, mineral trioxide aggregate, nonvital immature teeth, root strengthening

Treatment of young permanent teeth with pulpal involvement is an endodontic and restorative challenge. When pulp vitality is lost, dentin formation stops, resulting in a tooth with thin dentin walls that are prone to fracture.

Traditional apexification procedures used calcium hydroxide (1), and successful outcomes are reported (2–5). However, it is a lengthy procedure requiring 5 to 20 months (6) and multiple appointments. During this period, the tooth is restored temporarily with the risk of fracture (3). In addition, several *in vitro* studies reported a reduction in the mechanical properties of radicular dentin after exposure to calcium hydroxide for 5 weeks or longer (7).

Mineral trioxide aggregate (MTA) was introduced in 1993 (8) and has been studied extensively since that time. Its commercial introduction as ProRoot MTA began in 1998 (Tulsa Dental Specialties, Tulsa, Ok). It is part of a class of materials known as calcium silicate cements and is a bioactive material with excellent biocompatibility and antimicrobial properties with good sealing properties, even in the presence of moisture (9). MTA's drawbacks include a long setting time, handling properties that some clinicians describe as difficult, and dentin discoloration (9, 10).

MTA has been widely used as an apical barrier in immature, nonvital teeth as an alternative to calcium hydroxide apexification (10, 11). The apical MTA barrier technique has proven to be a successful and predictable procedure for nonvital immature teeth (11–15) in either 1 (12, 13) or 2 treatment sessions (13, 14). Several case series and prospective studies with MTA plugs reported high success rates at 1- and 2-year follow-ups (11–14). A recently published 10-year case series of 17 patients with nonvital, immature teeth showed that the apical plug technique was effective (15).

One of the concerns about the apical plug technique is whether teeth with thin dentinal walls are susceptible to root fracture after treatment (16). Studies have reported high short-term (11) and long-term (3) failure rates, primarily because of root fractures. This susceptibility to root fractures is often used as an argument to promote the use of revascularization/regeneration as an alternative treatment, with the possibility of continued hard tissue formation, root development, and strengthening of the

## Significance

Nonvital immature teeth treated with an MTA apical barrier and adhesive restorations healed and remained in function for up to 15 years with no fractures. It can be concluded that this treatment approach is viable and predictable for long-term tooth survival.

From the Private Practice, Purmerend, Netherlands; and Private Practice, San Antonio, Texas.

Address requests for reprints to Dr Marga H. Ree, 1444VH Purmerend, Netherlands. E-mail address: [andoree@planet.nl](mailto:andoree@planet.nl)  
0099-2399/\$ - see front matter

Copyright © 2017 American Association of Endodontists.  
<http://dx.doi.org/10.1016/j.joen.2017.02.017>

## Case Report/Clinical Techniques

**TABLE 1.** Diagnosis and Radiographic Findings

| Diagnosis, type of trauma/anomaly  | Number of teeth treated | Number of teeth with preoperative periapical radiolucency | Number of teeth without preoperative periapical radiolucency | Number of teeth with previous treatment | Number of teeth without previous treatment | Number of teeth recalled | Number of teeth without periapical radiolucency at recall | Number of teeth with periapical radiolucency at recall |
|--|-------------------------|---|--|---|--|--------------------------|---|--|
| (Un)complicated crown or crown/root fracture   | 13                      | 12  | 1  | 10                                      | 3  | 11                       | 10  | 1  |
| (Sub)luxation  | 26                      | 25  | 1  | 12                                      | 14   | 19                       | 19  | 0  |
| Horizontal root fracture   | 5                       | 5   | 0  | 5                                       | 0  | 5                        | 5   | 0  |
| Avulsion   | 9                       | 8   | 1  | 5                                       | 4  | 7                        | 7   | 0  |
| Intrusion  | 6                       | 5   | 1  | 1                                       | 5  | 6                        | 5   | 1  |
| More than 1 type of injury: (sub)luxation/intrusion/avulsion/horizontal root fracture AND (un)complicated crown or crown/root fracture | 21                      | 18  | 3  | 10                                      | 11   | 18                       | 17  | 1  |
| Dens invaginatus   | 3                       | 3   | 0  | 1                                       | 2  | 3                        | 3   | 0  |
| Total  | 83                      | 76  | 7  | 44                                      | 39   | 69                       | 66  | 3  |

root structure (17, 18). Although periapical healing on a radiograph is impressive, a true “patient-centered” outcome is long-term tooth retention after treatment, including normal function and comfort. Because there are limited long-term data in the endodontic literature on the “apical plug” technique, the first author, in 2015, undertook a recall of all the patients she treated with this technique in her practice between 2000 and 2010 (83 teeth in 72 patients, 5- to 15-year recalls). The results are reported in the sections that follow.

## Materials and Methods

### Patient/Tooth Characteristics

All of the patients in this case series were referred to the first author's private endodontic practice with at least 1 immature tooth in need of treatment. Between 2000 and 2010, a total of 83 teeth were treated in 72 patients (32 females and 40 males) with an age range of 7–27 years (mean age = 12.9 years).

Seventy-six of the 83 teeth presented preoperatively with an apical radiolucency. Of the remaining 7, 3 teeth were retreated because of an insufficient root canal filling; 2 because of a history of avulsion and intrusion, respectively; 1 because of a complicated crown/root fracture; and 1 because of symptoms after a prior pulpotomy. Of the 83 teeth in the study, 44 teeth had previous root canal treatment before the first consultation. They were obturated with gutta-percha and sealer (26 cases) or a calcium hydroxide dressing (13 cases) or left with an empty pulp canal space (5 cases). Thirty-nine teeth had not received any type of treatment (Table 1). Seventy-seven teeth had a diagnosis of apical periodontitis, 2 had necrotic pulps because of avulsion/intrusion, and 3 had insufficient root canal fillings without a periapical radiolucency. One tooth had a vital pulp, but root canal treatment was indicated for restorative reasons.

In the majority of cases, pulpal necrosis and subsequent apical periodontitis had been caused by a variety of traumatic dental injuries (Table 1). There were 3 teeth in the study that presented with dens invaginatus. In 1 of these, there was a history of trauma.

### Endodontic Treatment

The first author treated all of the patients in a similar manner. Informed consent was obtained from the patients and/or parents. Patients received conventional digital radiographs (Digora, Soredex Medical Systems, Helsinki, Finland) with an aiming device (Super-Bite; Kerr Corporation, Orange, CA). Some of the patients who were treated later (4/72) were also imaged with cone-beam computed tomographic imaging (Kodak 9000; Carestream Dental LLC, Atlanta, GA) for diagnostic reasons and more precise treatment planning. Standard testing established a pulpal and periapical diagnosis for each tooth. Periodontal probing, mobility assessment, and evaluation for cracks and fractures were also performed. If a sinus tract was present, it was traced with a gutta-percha point, and a periapical radiograph was made.

Treatment was generally performed in 3 sessions. When internal bleaching was indicated or when there were persistent signs and symptoms, 1 to 2 additional sessions were required.

In the first treatment session, local anesthesia was administered, and the tooth was isolated with a rubber dam. The tooth was accessed with a diamond bur in a high-speed handpiece, and very gentle mechanical (LightSpeed rotary instruments, marketed in its current form by Kerr Corporation) and chemical debridement was performed, including irrigation with sodium hypochlorite 5% (local compounding pharmacy). The apical foramen was gauged with a LightSpeed rotary instrument, and an apex locator (Elements-Diagnostic, Kerr Corporation) was used for electronic working length determination. The indication for an MTA plug was teeth with an apical foramen that gauged to size 70 (0.70 mm) or larger. Otherwise, a traditional root canal filling of gutta-percha and sealer was used. The canals were dried with paper points, an interappointment dressing of calcium hydroxide was applied (UltraCal XS; Ultradent, South Jordan, UT), and the tooth was temporized. The second session was scheduled 3 to 4 weeks later. The calcium hydroxide was removed with ultrasonically activated 5% sodium hypochlorite and 17% EDTA (Vista Dental Products, Racine, WI), and the working length was confirmed. If the patient was asymptomatic and a dry canal could be obtained, treatment proceeded. If those criteria

were not met,  $\text{Ca}(\text{OH})_2$  was replaced, and the patient was reappointed in 3 to 4 weeks.

For the apical plug, ProRoot MTA (Dentsply International, York, PA) was mixed according to the manufacturer's instructions and was applied to the apical portion of the root to a thickness of 4–5 mm with a Dovgan MTA gun (Hartzell and Son, Concord, CA). Thick paper points were used to condense the wet MTA and absorb the surplus moisture. Once a solid apical plug was obtained, a metal plugger was inserted against the MTA and activated with indirect ultrasonic energy. This has been shown to improve the adaptation to the canal walls (19, 20), create a denser plug (19), and enhance its physical properties (19–21). After verifying the position of the apical plug with a radiograph, a moist cotton pellet or sponge was inserted against the MTA, and the tooth was temporized. If the apical foramen was wide open, a so-called “blunderbuss,” an extraradicular apical matrix (barrier) of calcium sulfate (ACE Surgical Supply Co, Inc, Brockton, MA) was placed before the MTA with a Dovgan carrier to contain and prevent extrusion of the apical plug (22). Calcium sulfate is a good matrix material because it sets hard and is a biocompatible material that resorbs in a few weeks and has a long history of clinical use (23).

In the third session, it was verified that the MTA had fully set. If the clinical crown was discolored, an internal bleaching procedure was performed (34/83 cases) with the use of sodium perborate that was inserted for 2 weeks. When the color had returned to normal, 10% sodium ascorbate (local compounding pharmacy), a reducing agent, was applied for 3 minutes to reverse the oxidizing effects of the sodium perborate, which interferes with bonding (24, 25).

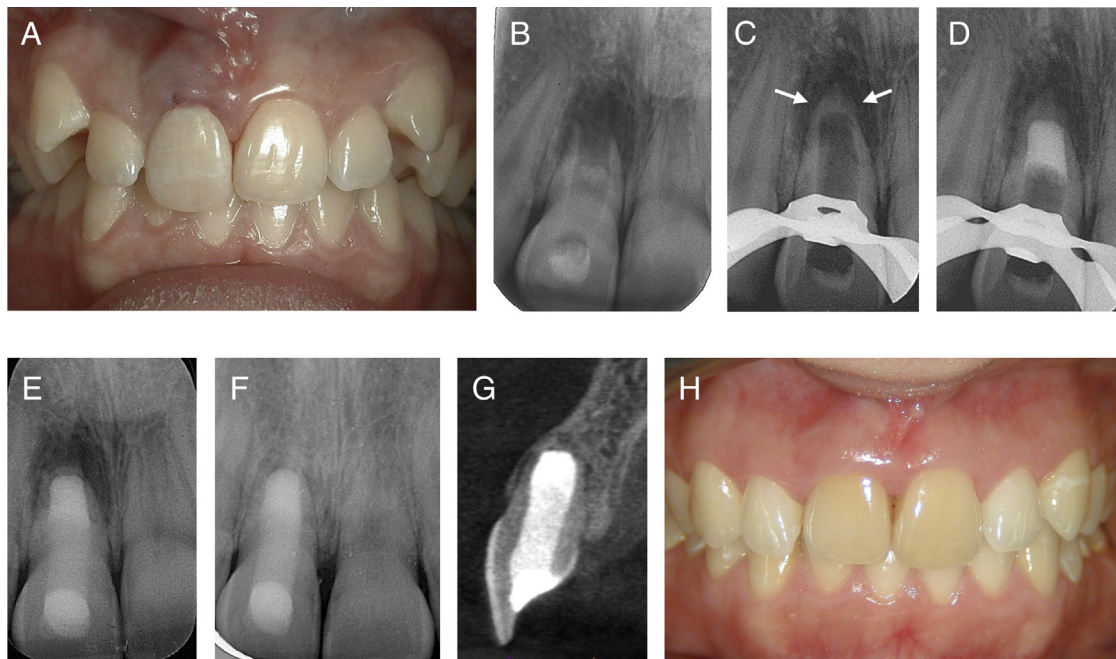
### Restorative Treatment

At the obturation appointment, the first author also restored the teeth. In 17 of 83 cases, the canal was backfilled with Resilon (Penron

Clinical Technologies, LLC Wallingford, CT) or gutta-percha followed by an adhesive access restoration. In 5 of 83 cases, an intermediate filling of gutta-percha or Resilon of 3- to 5-mm thickness was placed against the MTA before inserting a fiber post (DT Light-Post; RTD Corp, Saint Egreve, France). In 2 teeth, the restorative dentist removed the composite buildup and placed 2 cast metal post and cores before placing a crown. In 19 of 83 cases, the composite core material was placed directly against the set MTA plug, and in 40 of 83 cases 1 or more quartz fiber posts (DT Light-Post) were bonded into the canal against the set MTA.

When a fiber post was placed, the following protocol was used (26):

1. The dentin of the root canal walls and the pulp chamber was scrubbed with a microbrush with water and then sandblasted with a microetcher (Danville Material Inc, San Ramon, CA) with 50- $\mu\text{m}$  aluminum oxide particles.
2. The thickest post that fit passively into the post space was selected. If there was still space, additional posts were inserted and fitted (26, 27).
3. The root canal walls and pulp chamber were prepared for bonding with Ultra-Etch (30% phosphoric acid, Ultradent), SA primer and Photobond (Kuraray Noritake Dental Inc, Okayama, Japan), and a dual-cure bonding agent and light cured following the manufacturers' instructions.
4. The posts were soaked in 24% hydrogen peroxide for 1 minute, rinsed, and dried, and a ceramic primer was applied. This has been shown to improve the bond between the post and composite luting material (28).
5. The posts were bonded in the canals with LuxaCore (DMG, Hamburg, Germany), a composite core material, using either its self-cure or dual-cure version.
6. After the composite had polymerized, the posts were cut back to 2 mm under the cavosurface margin and covered with a hybrid



**Figure 1.** (A) A preoperative picture of a 15-year-old girl with a sinus tract at the labial aspect of tooth #8 after a traumatic dental injury at the age of 8. (B) A preoperative radiograph showing a periapical radiolucency associated with tooth #8 and a spontaneous revascularization of tooth #9. (C) The extraradicular barrier of calcium sulfate (*white arrows*). (D) The apical MTA plug. (E) A postoperative radiograph showing the completed treatment with a buildup of composite material against the apical MTA plug. (F) The 15-year follow-up. (G) Sagittal cone-beam computed tomographic slice showing the 15-year follow-up with complete healing. (H) A clinical picture of the 15-year recall showing a yellow discoloration of teeth #8 and #9.



## Case Report/Clinical Techniques

universal composite (Tetric Ceram; Ivoclar Vivadent, Schaan, Lichtenstein). If needed, the patient was referred to a restorative dentist for a definitive cosmetic restoration. An example of the endodontic and restorative procedures described can be seen in [Figures 1A–H, 2A–E](#) and [3A–F](#).

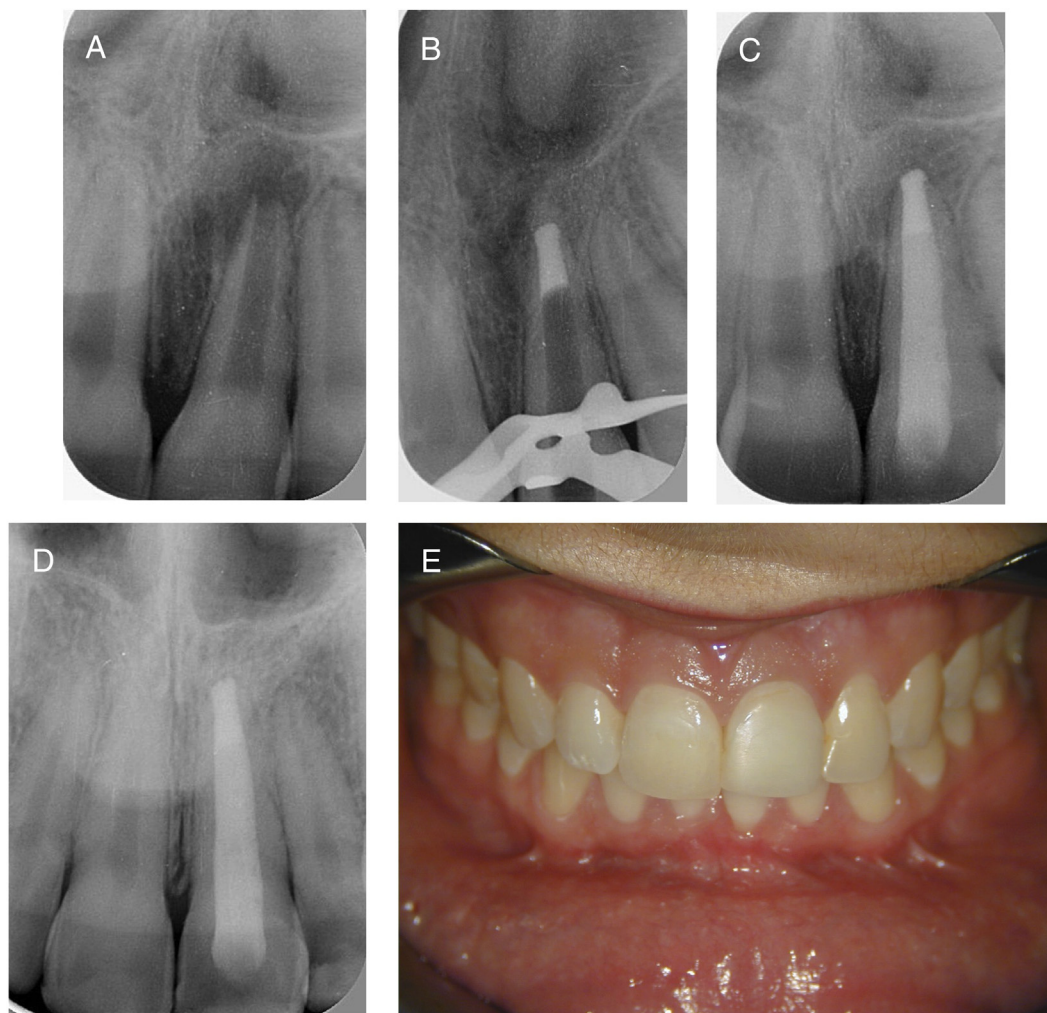
### Radiographic and Clinical Outcome Assessment

All 72 patients in this study were contacted after 5 to 15 years for recall appointments via email and/or phone calls. Twelve patients with a total number of 14 treated teeth could not be scheduled for a follow-up. Nine of the 12 patients confirmed on the telephone that their treated tooth was still present ([Fig. 4](#)). They declined recall appointments stating lack of symptoms and lack of time as the main reasons for not attending. At recall, patients were evaluated for the presence or absence of clinical signs and symptoms such as spontaneous pain, tenderness to pressure or percussion, sinus tract, root or tooth fracture, discoloration, loss of function, mobility, or probing depths. The quality of the coronal restoration was assessed radiographically and by visual inspection under a microscope. The radiographic evaluation included the presence or absence of periradicular radiolucent areas, signs of resorption, alveolar bone loss, and root fractures. Dichotomized outcome

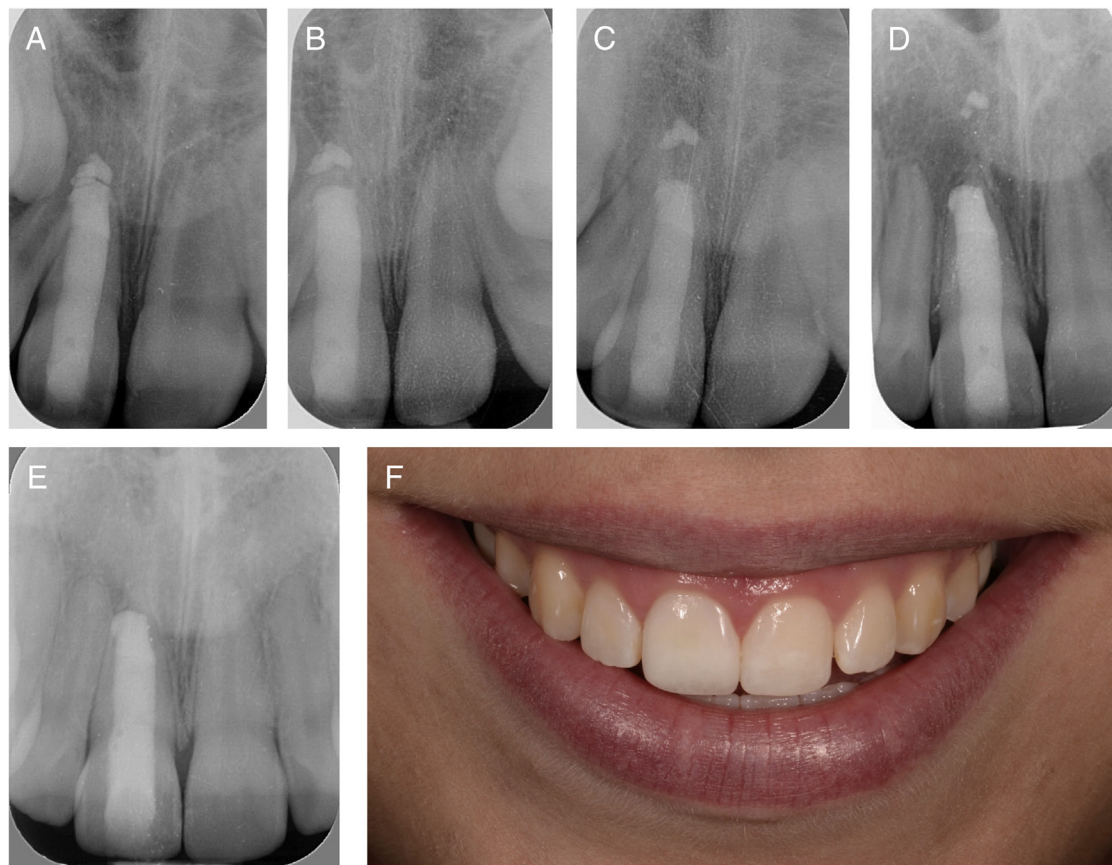
criteria included “healed” (asymptomatic with absence of signs of infection or periapical radiolucency and no apical periodontal ligament thickening wider than twice the normal width in unaffected areas) and “not healed” (symptomatic, evidence of infection, and periapical radiolucency or widened periodontal ligament space present).

### Results

The patient flow diagram is shown in [Figure 4](#). All teeth that gauged to a size 70 or larger were assessed for eligibility for the apical MTA plug technique. All such teeth were allocated to receive the described technique. All allocated teeth received the allocated intervention. Follow-up was attempted for all patients. Of 83 teeth, 69 teeth in 60 patients were available for follow-up after 5 to 15 years (recall rate = 83%). Patient demographics are shown in [Table 2](#), and the distribution by tooth type is shown in [Table 3](#). The mean follow-up time was 8.29 years. Clinical examination revealed that 59 of 60 patients were asymptomatic. No teeth were lost because of root fracture. One of the 69 teeth was lost because of replacement resorption. A decoronation and root submergence procedure was performed. Radiographic examination identified 3 teeth with periradicular radiolucent areas (96% were characterized as healed) ([Table 1](#)). One of these was treated successfully with surgery.



**Figure 2.** (A) A preoperative radiograph showing a periapical radiolucency associated with tooth #9 after luxation. (B) The extraradicular barrier of calcium sulfate and an apical MTA plug. (C) A postoperative radiograph after fiber post placement and a composite buildup. (D) The 9-year follow-up. (E) A clinical picture at the 9-year follow-up showing a buccal veneer of resin composite on tooth #9.



**Figure 3.** (A) A postoperative radiograph of root canal treatment in tooth #8 in a 7-year old girl showing extrusion of MTA. (B) The 1-year follow-up. (C) The 2-year follow-up. (D) The 6-year follow-up; the extruded MTA particles are partially dissolved. (E) The 10-year follow-up; the extruded MTA particles are almost completely dissolved. (F) A clinical picture at the 10-year follow-up after internal bleaching and a new class 4 restoration of composite resin. Restorative treatment by Dr Marta Ilik, Amsterdam.

Three of the 69 teeth showed signs of invasive cervical resorption (ICR). Of these 3 teeth, 1 sustained a horizontal root fracture, 1 was avulsed, and 1 had a luxation injury. In all 3 cases, the patient was asymptomatic, and the periradicular radiolucency was resolved; therefore, they were included in the “healed category.” Three teeth were determined to have signs of replacement resorption (RR), 2 from the avulsion group and 1 that was intruded. One of the teeth with RR had significant gingival recession. These 3 teeth were also included in the “healed category” for similar reasons as the teeth with ICR. Six teeth had preoperative inflammatory root resorption, which arrested after treatment, and at recall they had continuous, normal-looking periodontal ligaments.

The definitive restorative treatment was as follows: 8 of the 69 teeth were restored with porcelain or composite veneers, 6 with full-coverage crowns, 31 with a class 3 or 4 composite restoration, and 24 with an access restoration of composite resin (Table 4). Thirty of the 69 teeth had a slight to moderate yellow (22/69) or gray discoloration (8/69) of the clinical crown.

## Discussion

The primary objective of nonsurgical root canal therapy in teeth with incomplete root formation is long-term tooth retention. In most children and adolescents, there are very limited restorative options after tooth loss. In treating immature teeth, the goal is usually to retain the tooth at least until the patient reaches their early 20s when jaw growth

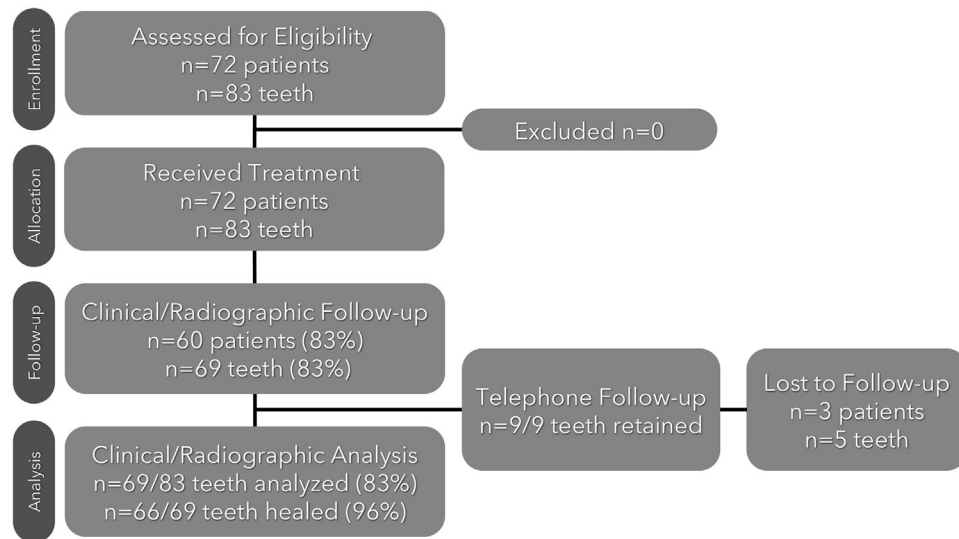
is largely complete and implants and other restorative options become viable (29).

Six teeth showed radiographic signs of ICR or RR. One tooth with RR was decoronated because of severe infraposition as recommended by Malmgren (30). The other 5 were still in function and asymptomatic 7 to 10 years after treatment was performed. All 6 teeth were categorized as “healed.” The resorption was an interesting finding but probably unrelated to the author’s treatment. The resorption may be caused by the initial trauma or subsequent orthodontic treatment that was performed in 5 of 6 patients. None of the teeth in the ICR group received internal bleaching. Nine additional patients (with 9 teeth) who were contacted by telephone declined a recall appointment but reported that their teeth remained asymptomatic and functional (Fig. 4). This suggests that at least an additional 9 teeth survived.

## MTA versus $\text{Ca(OH)}_2$

The traditional approach of apexification with calcium hydroxide has a high success rate if the patients are compliant (2, 31) but has significant potential disadvantages, including multiple treatment sessions and a lengthy treatment time (6), the difficulty of maintaining the integrity of the coronal seal in between appointments, and noncompliant patients (32). In addition, the long-term application of calcium hydroxide is reported to weaken the tooth and increase the likelihood of tooth fracture (3, 7). According to 2 studies, an MTA plug does not negatively impact the fracture resistance of dentin (33, 34).

## Case Report/Clinical Techniques



**Figure 4.** Flow diagram of all patients at each stage of the case series.

El Meligy and Avery (4) directly compared the MTA plug with the traditional  $\text{Ca}(\text{OH})_2$  apexification technique. They treated children with 2 permanent incisors diagnosed with necrotic pulps by placing an MTA barrier in 1 incisor and performing  $\text{Ca}(\text{OH})_2$  apexification in the other. Their findings indicated that at 12-month recalls 13 of 15 teeth treated with  $\text{Ca}(\text{OH})_2$  were symptom free and radiographically successful versus 15 of 15 teeth treated with MTA plugs. The 2 techniques were statistically equivalent.

Pradhan et al (5) compared the healing times of MTA root-end barriers and  $\text{Ca}(\text{OH})_2$  apexification. Their results indicated the modalities had similar healing times, but the treatment times were significantly shorter for the MTA group. In a more recent prospective, randomized clinical trial (11), MTA and calcium hydroxide were compared for inducing root apex closure in immature necrotic permanent incisors. There was no difference at the 6-month examination, but at 12 months the MTA group displayed better apical closure. In the calcium hydroxide group, 4 of 15 teeth exhibited coronal or radicular fractures after 12 months.

### The MTA Plug Technique versus Regenerative Endodontic Procedures

The success rate of an apical MTA plug is reported to vary between 81% and 100% at 1- and 2-year follow-ups (4, 5, 11–14). In the case series by Pace et al (15), complete healing was observed in 7 of 17 teeth at the 1-year follow-up and 13 of 16 teeth at 5 years. The results were slightly improved at 10 years (15/16 teeth). One tooth had been extracted because of a longitudinal root fracture. The results of the present study are largely in agreement with the findings of Pace et al.

**TABLE 2.** Patient Demographics of the Recall Group

| Demographics      | Number |
|-------------------|--------|
| Sex demographics  |        |
| Females, <i>n</i> | 28     |
| Males, <i>n</i>   | 32     |
| Age demographics  |        |
| Range, <i>y</i>   | 7–27   |
| Average, <i>y</i> | 12.3   |

In articles discussing regenerative endodontic procedures (REPs), it is frequently mentioned that the MTA barrier technique neither strengthens the root nor fosters further root development, suggesting the need for regenerative endodontics to help avoid root fractures (16, 35). In a recent article, REP was recommended as the first treatment option for immature teeth with pulp necrosis (36). In the present study of 83 immature teeth, no teeth were lost because of root fracture, suggesting that root fracture is not a significant problem if the clinician follows the first author's endodontic/restorative protocol.

A systematic review and meta-analysis compared apexification with calcium hydroxide, the MTA plug technique, and REP using a blood clot, platelet-rich plasma, or platelet-rich fibrin as a scaffold. The analysis compared clinical and radiographic outcomes, and the results favored the MTA apexification over calcium hydroxide apexification and REPs (37).

Although case reports and case series on REPs provide exciting and promising results, a possible concern about REPs is that when successful increases of root thickness are usually limited to apical and mid-root areas. Functional (and parafunctional) forces concentrate at the crest of the alveolar bone (38, 39), making these areas the most susceptible to fracture, but REP rarely generates any additional dentin thickness in this area.

### Reinforcing Effect of Post and Composite Core

There is substantial evidence that the postendodontic restorative treatment can enhance the fracture resistance of thin-walled and weak teeth. Adhesively bonded composite resin restorations extended into the root canal space have been shown to enhance the strength of immature teeth (40). Additional *in vitro* studies showed that the use of fiber posts improved the fracture resistance of immature teeth significantly more than composite resin alone (41–43). Backfilling the remaining part of the root canal with gutta-percha and sealer resulted

**TABLE 3.** Tooth Type of the Recall Group

| Tooth type         | Number of teeth |
|--------------------|-----------------|
| Maxillary incisor  | 65              |
| Mandibular incisor | 3               |
| Mandibular canine  | 1               |



**TABLE 4.** Type of Restorative Treatment

| Type of build-up  | Number of teeth treated | Number of teeth recalled | Number of teeth with veneer at recall | Number of teeth with full crown at recall | Number of teeth with class 3 or 4 composite restoration at recall | Number of teeth with only a restored access opening at recall |
|---|-------------------------|--------------------------|---------------------------------------|---|---|---|
| Composite with intermediate filling of gutta-percha or Resilon          | 17                      | 14                       | 3                                     | 0   | 7   | 4   |
| Composite on top of MTA plug  | 19                      | 18                       | 0                                     | 1   | 7   | 10  |
| Fiber post, composite, intermediate filling of gutta-percha, or Resilon | 5                       | 4                        | 0                                     | 1   | 2   | 1   |
| Fiber post and composite on top of MTA plug                             | 40                      | 31                       | 5                                     | 2   | 15  | 9   |
| Metal post, intermediate filling of gutta-percha                        | 2                       | 2                        | 0                                     | 2   | 0   | 0   |
| Total   | 83                      | 69                       | 8                                     | 6   | 31  | 24  |

MTA, mineral trioxide aggregate.

in the weakest roots (41–43). The benefit of fiber posts to increase the fracture resistance of pulpless teeth has been reported in numerous studies and recommended by many authors (38, 41–47). These *in vitro* findings are supported by the results of this clinical study.

### Extrusion of MTA

An interesting finding was that when MTA was unintentionally extruded into the periapical tissues, it appeared to dissolve over time (Fig. 3). This finding was also reported in several case reports (48, 49). A possible explanation is that the cement particles are not bound into an insoluble mass when MTA is extruded and is probably diluted by body fluids. When cement is very dilute, it will not set (50). Dissolution of MTA in contact with tissue fluids was also shown in a recent animal study (51).

### Color Stability

A common finding at recall examinations was a slight to moderate yellow (22/69) discoloration of the clinical crown (Fig. 1H). In some cases, there was a gray (8/69) discoloration (Fig. 2E). Several factors probably contributed to this. Discoloration is commonly associated with traumatized teeth (52). Internal bleaching was performed in 34 of 83 (40%) of the teeth before the placement of the adhesive restorations. Recurrence of discoloration is fairly common after intracoronal bleaching and is reported to occur in up to 37% of all cases (53). Composites are susceptible to color change over time, particularly self-cure and dual-cure composites, because of hydrolysis (54) exposure to ultraviolet light (55), uptake of staining substances from food and drinks (56), and the type of accelerator (57). In addition, it may be hypothesized that the light-transmitting properties of these teeth may have been affected by the presence of an opacous composite material in the large pulp chamber. In several cases (10/69), the discoloration was successfully treated with an internal bleaching procedure after recall. The author informed all patients concerned about discoloration of the option of internal bleaching. The majority of patients declined.

In summary, 83 immature teeth were treated over a 10-year period using an MTA barrier and adhesive restorations. Of those, 69 were recalled and examined (83% recall rate), and 96% (66/69) were deemed

to be healed and were in function for 5 to 15 years (mean of 8.29 years). An important finding was that none of the teeth sustained fractures. These results show that this is a viable and predictable treatment approach for long-term success of nonvital immature teeth.

### Acknowledgments

*The authors thank Martin Trope, DMD (Private Practice limited to Endodontics, Philadelphia, PA) for his valuable support during the preparation of this article.*

*The authors deny any conflicts of interest related to this study.*

### References

- Frank AL. Therapy for the divergent pulpless tooth by continued apical formation. *J Am Dent Assoc* 1966;72:87–93.
- Cvek M. Treatment of non-vital permanent incisors with calcium hydroxide. I. Follow-up of periapical repair and apical closure of immature roots. *Odontol Revy* 1972;23:27–44.
- Cvek M. Prognosis of luxated non-vital maxillary incisors treated with calcium hydroxide and filled with gutta-percha: a retrospective clinical study. *Endod Dent Traumatol* 1992;8:45–55.
- El Meligy OA, Avery DR. Comparison of apexification with mineral trioxide aggregate and calcium hydroxide. *Pediatr Dent* 2006;28:248–53.
- Pradhan DP, Chawla HS, Gauba K, Goyal A. Comparative evaluation of endodontic management of teeth with unformed apices with mineral trioxide aggregate and calcium hydroxide. *J Dent Child (Chic)* 2006;73:79–85.
- Sheehy EC, Roberts GJ. Use of calcium hydroxide for apical barrier formation and healing in non-vital immature permanent teeth: a review. *Br Dent J* 1997;183:241–6.
- Yassen GH, Platt JA. The effect of nonsetting calcium hydroxide on root fracture and mechanical properties of radicular dentine: a systematic review. *Int Endod J* 2013;46:112–8.
- Lee SJ, Monsef M, Torabinejad M. Sealing ability of a mineral trioxide aggregate for repair of lateral root perforations. *J Endod* 1993;19:541–4.
- Parirokh M, Torabinejad M. Mineral trioxide aggregate: a comprehensive literature review—part I: chemical, physical and antibacterial properties. *J Endod* 2010;36:16–7.
- Parirokh M, Torabinejad M. Mineral trioxide aggregate: a comprehensive literature review—part III: clinical applications, drawbacks, and mechanism of action. *J Endod* 2010;36:400–13.
- Bonte E, Beslot A, Boukpepsi T, Lasfargues JJ. MTA versus Ca(OH)<sub>2</sub> in apexification of non-vital immature permanent teeth: a randomized clinical trial comparison. *Clin Oral Invest* 2015;19:1381–8.

## Case Report/Clinical Techniques

12. Simon S, Riillard F, Berdal A, et al. The use of mineral trioxide aggregate in one-vit apexification treatment: a prospective study. *Int Endod J* 2007;40:186–97.
13. Witherspoon DE, Small JC, Regan JD, et al. Retrospective analysis of open apex teeth obturated with mineral trioxide aggregate. *J Endod* 2008;34:1171–6.
14. Moore A, Howley MF, O'Connell AC. Treatment of open apex teeth using two types of white mineral trioxide aggregate after initial dressing with calcium hydroxide in children. *Dent Traumatol* 2011;27:166–73.
15. Pace R, Giuliani V, Nieri M, et al. Mineral trioxide aggregate as apical plug in teeth with necrotic pulp and immature apices: a 10-year case series. *J Endod* 2014;40:1250–4.
16. Jeeruphan T, Jantaraj J, Yanpiset K, et al. Mahidol study I: comparison of radiographic and survival outcomes of immature teeth treated with either regenerative endodontic or apexification methods: a retrospective study. *J Endod* 2012;38:1330–6.
17. Hargreaves K, Law A. Regenerative endodontics. In: Hargreaves K, Cohen S, eds. *Pathways of the Pulp*, 10th ed. St Louis, MO: Mosby Elsevier; 2011:602–19.
18. Huang GT. Apexification: the beginning of its end. *Int Endod J* 2009;42:855–66.
19. Parashos P, Phoon A, Sathorn C. Effect of ultrasonication on physical properties of mineral trioxide aggregate. *Biomed Res Int* 2014;2014:191984.
20. Escribano-Escrivá B, Micó-Muñoz P, Manzano-Saiz A, et al. MTA apical barrier: *in vitro* study of the use of ultrasonic vibration. *J Clin Exp Dent* 2016;8:e318–21.
21. Kiiçükkaya Eren S, Aksel H, Serper A. Effect of placement technique on the push-out bond strength of calcium-silicate based cements. *Dent Mater J* 2016;35:742–74.
22. Alhadainy HA, Abdalla AI. Artificial floor technique used for the repair of furcation perforations: a microleakage study. *J Endod* 1998;24:33–5.
23. Pietrzak WS, Ronk R. Calcium sulfate bone void filler: a review and a look ahead. *J Craniofac Surg* 2000;11:327–33.
24. Lima AF, Fonseca FM, Freitas MS, et al. Effect of bleaching treatment and reduced application time of an antioxidant on bond strength to bleached enamel and subjacent dentin. *J Adhes Dent* 2011;13:537–42.
25. Trindade TF, Moura LK, Raucci W Neto, et al. Bonding effectiveness of universal adhesive to intracoronary bleached dentin treated with sodium ascorbate. *Braz Dent J* 2016;27:303–8.
26. Ree M, Schwartz RS. The endo-restorative interface: current concepts. *Dent Clin North Am* 2010;54:345–74.
27. Porciani PF, Vano M, Radovic I, et al. Fracture resistance of fiber posts: combinations of several small posts vs. standardized single post. *Am J Dent* 2008;21:373–6.
28. de Sousa Menezes M, Queiroz EC, Soares PV, et al. Fiber post etching with hydrogen peroxide: effect of concentration and application time. *J Endod* 2011;37:398–402.
29. Fudalej P, Kokich VG, Leroux B. Determining the cessation of vertical growth of the craniofacial structures to facilitate placement of single-tooth implants. *Am J Orthod Dentofacial Orthop* 2007;131(4 Suppl):S59–67.
30. Malmgren B. Ridge preservation/decoronation. *J Endod* 2013;39(3 Suppl):S67–72.
31. Rafter M. Apexification: a review. *Dent Traumatol* 2005;21:1–8.
32. Heling I, Lustmann J, Hover R, Bichacho N. Complications of apexification resulting from poor patient compliance: report of case. *J Dent Child* 1999;66:415–8.
33. Andreasen JO, Munksgaard EC, Bakland LK. Comparison of fracture resistance in root canals of immature sheep teeth after filling with calcium hydroxide or MTA. *Dent Traumatol* 2006;22:154–6.
34. Tuna EB, Dinçol ME, Gençay K, et al. Fracture resistance of immature teeth filled with BioAggregate, mineral trioxide aggregate and calcium hydroxide. *Dent Traumatol* 2011;27:174–8.
35. Hargreaves KM, Diogenes A, Teixeira FB. Treatment options: biological basis of regenerative endodontic procedures. *Pediatr Dent* 2013;35:129–40.
36. Diogenes A, Ruparel NB, Shiloah Y, Hargreaves KM. Regenerative endodontics: a way forward. *J Am Dent Assoc* 2016;147:372–80.
37. Nicoloso GF, Pötter IG, Rocha RO, et al. A comparative evaluation of endodontic treatments for immature necrotic permanent teeth based on clinical and radiographic outcomes: a systematic review and meta-analysis. *Int J Paediatr Dent* 2017;27:217–27.
38. Dietschi D, Duc O, Krejci I, Sadan A. Biomechanical considerations for the restoration of endodontically treated teeth: a systematic review of the literature—part I. Composition and micro- and macrostructure alterations. *Quintessence Int* 2007;38:733–43.
39. Talati A, Disfani R, Afshar A, Fallah Rastegar A. Finite element evaluation of stress distribution in mature and immature teeth. *Iran Endod J* 2007;2:47–53.
40. Desai S, Chandler N. The restoration of permanent immature anterior teeth, root filled using MTA: a review. *J Dent* 2009;37:652–7.
41. Schmoltdt SJ, Kirkpatrick TC, Rutledge RE, Yaccino JM. Reinforcement of simulated immature roots restored with composite resin, mineral trioxide aggregate, gutta-percha, or a fiber post after thermocycling. *J Endod* 2011;37:1390–3.
42. Brito-Júnior M, Pereira RD, Veríssimo C, et al. Fracture resistance and stress distribution of simulated immature teeth after apexification with mineral trioxide aggregate. *Int Endod J* 2014;47:958–66.
43. Nikhil V, Jha P, Aggarwal A. Comparative evaluation of fracture resistance of simulated immature teeth restored with glass fiber posts, intracanal composite resin, and experimental dentine posts. *ScientificWorldJournal* 2015;2015:751425.
44. Tanalp J, Dikbas I, Malkondu O, et al. Comparison of the fracture resistance of simulated immature permanent teeth using various canal filling materials and fiber posts. *Dent Traumatol* 2012;28:457–64.
45. Cauwels RG, Lassila LV, Martens IC, et al. Fracture resistance of endodontically restored, weakened incisors. *Dent Traumatol* 2014;30:348–55.
46. Dikbas I, Tanalp J, Koksall T, et al. Investigation of the effect of different prefabricated intracanal posts on fracture resistance of simulated immature teeth. *Dent Traumatol* 2014;30:49–54.
47. Sivieri-Araujo G, Tanomaru-Filho M, Guerreiro-Tanomaru JM, et al. Fracture resistance of simulated immature teeth after different intra-radicular treatments. *Braz Dent J* 2015;26:211–5.
48. Asgary S, Ehsani S. MTA resorption and periradicular healing in an open-apex incisor: a case report. *Saudi Dent J* 2012;24:55–9.
49. Nosrat A, Nekoofar MH, Bolhari B, Dummer PM. Unintentional extrusion of mineral trioxide aggregate: a report of three cases. *Int Endod J* 2012;45:1165–76.
50. Camilleri J, Formosa L, Damidot D. The setting characteristics of MTA Plus in different environmental conditions. *Int Endod J* 2013;46:831–40.
51. Schembri Wismayer P, Lung CY, Rappa F, et al. Assessment of the interaction of Portland cement-based materials with blood and tissue fluids using an animal model. *Sci Rep* 2016;6:34547.
52. Abbott P, Heah SY. Internal bleaching of teeth: an analysis of 255 teeth. *Aust Dent J* 2009;54:326–33.
53. Amato M, Scaravilli MS, Farella M, Riccitello F. Bleaching teeth treated endodontically: long-term evaluation of a case series. *J Endod* 2006;32:376–8.
54. Asmussen E. Factors affecting the color stability of restorative resins. *Acta Odontol Scand* 1983;41:11–8.
55. Brauer GM. Color changes of composites on exposure to various energy sources. *Dent Mater* 1988;4:55–9.
56. Fay RM, Servos T, Powers JM. Color of restorative materials after staining and bleaching. *Oper Dent* 1999;24:292–6.
57. Tanoue N, Koishi Y, Yanagida H, et al. Color stability of acrylic resin adhesives with different initiation modes. *Dent Mater J* 2004;23:368–72.